

Location and Causation of Residual Lymph Node Metastasis After Surgical Treatment of Regionally Advanced Differentiated Thyroid Cancer

Jessa E. Miller,¹ Neal C. Al-Attar,¹ Owen H. Brown,¹ Gabrielle G. Shaughnessy,¹
Natalja P. Rosculec,¹ Anca M. Avram,^{1,2} and David T. Hughes^{1,3}

Background: After initial surgical treatment of differentiated thyroid cancer (DTC) residual lymph node metastases are often found at the time of radioactive iodine (¹³¹I) therapy. Recurrence of DTC is due to persistent disease not removed at initial surgery which also did not respond to ¹³¹I treatment. This study aimed at determining locations of, and reasons for, residual nodal metastases detected by ¹³¹I scans with single-photon emission computed tomography (SPECT/CT) obtained prior to radioiodine therapy following surgical treatment of DTC.

Methods: This is a retrospective study of 352 patients with intermediate and high-risk DTC treated with ¹³¹I therapy at the University of Michigan from 2007 to 2014. All patients underwent total thyroidectomy with or without lymph node dissection followed by radioiodine therapy. Pre-ablation diagnostic ¹³¹I scans with SPECT/CT were used postoperatively to localize nodal metastases, which were then compared with the cervical lymph node basins dissected at the time of surgery to determine the reason for residual nodal metastases: incomplete nodal dissection versus preoperative unrecognized nodal metastases.

Results: Of the 352 patients in the study, 146 (41.5%) had residual nodal metastases detected on ¹³¹I scans with SPECT/CT following initial surgery but prior to ¹³¹I therapy. Among the 146 patients with residual disease, there were a total of 218 distinct nodal metastases. Relative to the primary tumor, 71.6% ($n=156$) of metastases were ipsilateral, 22.0% ($n=48$) were contralateral, and 6.4% ($n=14$) were non-sided in the central neck (level VI/VII). Cervical lymph node levels VI, III, and II had the greatest frequencies of residual metastases (33.9%, 22.9%, 18.8%, respectively). Residual metastases occurred because of incomplete nodal dissection (49.3%), lack of preoperative identification (37.7%), or a combination of both (13%).

Conclusion: Residual nodal metastasis following initial surgical treatment for regionally advanced differentiated thyroid cancer is rather common on highly sensitive ¹³¹I scans with SPECT/CT and is due to both unrecognized nodal involvement preoperatively and incomplete removal of metastatic lymph nodes during compartment-orientated nodal dissection. The surgical management of high-risk DTC should include preoperative imaging to evaluate for nodal metastases in the central and lateral neck and compartment-orientated nodal dissection of involved compartments. Attention should be given to complete dissection in levels VI, III, and II, particularly when dissecting compartments ipsilateral to the primary tumor.

Keywords: thyroid cancer, thyroidectomy, radioiodine, persistent thyroid cancer, papillary thyroid cancer surgery, lymph node dissection

Introduction

APPROXIMATELY 63,000 NEW CASES of thyroid cancer occur in the United States each year, and more than 90% are due to differentiated thyroid cancer (DTC). Cervical lymph node metastasis occurs in 20–50% of patients with

DTC and this nodal involvement varies from clinically relevant macrometastasis to seemingly clinically irrelevant micrometastasis noted only after prophylactic central neck dissection (1–3). The prognostic implications of regional lymph node metastasis in patients with papillary thyroid cancer include higher rates of recurrent disease, the need for

¹University of Michigan Medical School, Departments of ²Nuclear Medicine and ³Surgery, University of Michigan Health System, Ann Arbor, Michigan.

additional treatment with surgery and/or radioiodine, and an increase in relative risk of death (4–7). In patients with preoperative evidence of lymph node metastasis on physical exam and/or imaging studies, total thyroidectomy with compartment-orientated lymph node dissection and compartment-orientated removal of malignant lymph nodes is the standard of care and is recommended by the American Thyroid Association guidelines for the treatment of DTC (1). This compartment-orientated approach to resection of lymph node metastases typically includes central compartment (level VI) or central and lateral compartment (levels II–V) dissection, depending on the extent of disease.

Despite attempts to resect all regional metastatic disease at the time of initial surgical therapy, residual malignant lymph nodes are often found on imaging at the time of radioactive iodine (RAI) treatment (5). Single-photon emission computed tomography (SPECT/CT) is an imaging modality with an image contrast resolution that is superior to earlier gamma cameras and is used to enhance the sensitivity of ^{131}I (RAI) scanning to diagnose lymph node metastases postoperatively. SPECT/CT features include improved intrinsic resolution, scatter rejection technology, iterative reconstruction, and CT-based attenuation correction algorithms for SPECT which allows for detailed anatomic localization of residual lymph node metastasis after surgery and may be more sensitive in detection of small lymph node metastasis than ultrasound or CT imaging (5). Residual nodal metastases after initial surgery can occur in both dissected and undissected lymph node compartments and are therefore due to lack of recognition of lymph node involvement on preoperative assessment with physical exam and imaging, or intraoperatively during direct inspection of lymph nodes during thyroidectomy. Alternatively, residual nodal metastasis can also be due to incomplete removal of involved lymph nodes in a surgically dissected nodal compartment, such that metastatic lymph nodes are left behind when performing lymph node dissection.

Persistent lymph node metastasis after initial surgical treatment and radioiodine therapy is the most common etiology of recurrent disease (1). Therefore, recurrent DTC is persistent disease that was not removed at initial surgery and that did not respond to radioactive iodine treatment. The completeness of surgical resection is an important determinant of outcomes because residual lymph node metastases represent the most common site of disease persistence and recurrence of DTC (5,8,9). Additionally, persistent lymph node metastases often lose the ability to concentrate radioiodine, rendering additional RAI treatments ineffective (10). Consequently, persistent cervical lymph node metastases that do not respond to RAI therapy usually require reoperation if residual disease is of significant size and volume to have clinical relevance (11).

In an effort to further the understanding of persistent lymph node metastasis after initial surgery treatment, this study analyzed the postsurgical radioiodine SPECT/CT scan results in patients with intermediate and high-risk DTC prior to administration of ^{131}I therapy. The first aim of this study was to identify the most common anatomic locations of persistent lymph node metastases following initial surgical treatment of intermediate and high-risk DTC. The second aim of this study was to identify the primary reasons for residual malignant lymph nodes following initial surgical treatment of intermediate and high-risk DTC which was deemed to be

either due to preoperatively unrecognized nodal involvement and omission of nodal dissection or due to incomplete surgical dissection of the involved lymph nodes.

Methods

Following institutional review board approval, a retrospective chart review of all patients with intermediate or high-risk DTC treated with RAI at the University of Michigan Health System between 2007 and 2014 was performed. High and intermediate-risk DTC was defined by the American Thyroid Association (ATA) in 2009 as a tumor with any of the following characteristics: $\geq\text{T2}$ stage, N1a or N1b stage, any extrathyroidal extension, or vascular invasion (6). This study population included patients with a diagnosis of papillary, follicular, or Hürthle cell thyroid cancer who were treated with adjuvant radioiodine therapy following initial surgery. Patients not receiving radioiodine therapy were excluded from this study; therefore, patients with low-risk DTC without an indication for postoperative radioiodine were not included in this study. Patients having more than one surgical procedure prior to RAI treatment, besides completion thyroidectomy after hemithyroidectomy, were also excluded from this study.

Surgery was performed at either the University of Michigan or at an outside institution and included total thyroidectomy with or without a lymphadenectomy as dictated by the clinical extent of disease noted on preoperative exam and imaging studies. The decision to perform a lymph node dissection was based on preoperative evidence of lymph node involvement by physical exam and any imaging that was available for each patient, including cervical ultrasound and cross-sectional imaging with CT, MRI, or PET/CT. The appearance of metastatic cervical lymph nodes on ultrasound included a hypoechoic, rounded appearance with loss of fatty hilum, microcalcifications or cystic change. On CT scan, metastatic lymph nodes have an enlarged, rounded appearance and enhancement with intravenous contrast. Patients with preoperative evidence of level VI or VII lymph node metastasis had a bilateral central neck dissection and patients with lateral neck nodal involvement (levels II–V) had a compartment-orientated lateral neck dissection in addition to a central neck dissection. Prophylactic central neck dissection was performed at the discretion of the surgeon. Although prophylactic central neck dissection was typical at the University of Michigan during the study period, similar decisions regarding patients referred from outside institutions were at the discretion of those providers. The decision to recommend radioiodine therapy was made by the referring physician after surgical pathology was available and was based on national guidelines (1).

A retrospective review of patients' medical records including clinic notes, operative reports, pathology reports, radiology reports, and outside hospital documents was performed. The lobe(s) involved by the primary tumor were classified into 6 distinct categories: left, right, multifocal, isthmus, pyramidal, and unspecified. Multifocal primary tumors were defined as those with more than one focus of DTC and included all tumor sizes. The extent of surgery (total thyroidectomy with or without central or lateral neck dissection) and the pathologic staging based on operative

pathology using American Joint Committee on Cancer staging criteria for DTC was noted.

After surgery, all patients underwent postoperative preablation ^{131}I scans with SPECT/CT (diagnostic scans) per the University of Michigan institutional protocol. Planar whole-body scan and static neck and chest images were acquired in anterior and posterior projections at 24 hours after oral administration of 1 mCi (37 MBq) ^{131}I . All patients underwent routine SPECT/CT imaging with an axial field of view extending from the skull base to the diaphragm. All abnormal activity foci seen on planar scans outside of the neck and chest were also evaluated with SPECT/CT. Post-treatment whole-body scan and static neck and chest images were obtained at 2–3 days post-therapy in all patients to determine therapeutic ^{131}I localization, and the results were correlated with the diagnostic scans. Patients then received radioiodine treatment, and the prescribed therapeutic ^{131}I activity (median dose = 150 mCi; range 30–500 mCi) was based on all available information (histopathology, stimulated thyroglobulin, and findings on diagnostic scans).

The primary outcome for this study was the presence of residual lymph node metastasis detected on ^{131}I SPECT/CT obtained after initial surgery, but before treatment with therapeutic ^{131}I . Therefore, the efficacy of radioiodine therapy on the treatment of these residual metastasis was not a primary outcome measure of this study. The diagnostic and immediate post-treatment scans were reviewed for the presence of remnant thyroid tissue, residual tumor in the thyroid bed, residual lymph node metastases, and distant metastases. The anatomic location of iodine-avid cervical nodal metastases was determined using a standardized classification system proposed by the American Head and Neck Society and the American Academy of Otolaryngology–Head and Neck Surgery (12). Residual lymph node metastasis was defined as any residual activity noted on either RAI scan as iodine-avid nodules or suspicious lymph nodes noted on SPECT/CT which did not concentrate ^{131}I . There were no patients with primary tumor recurrence in the thyroid bed in the absence of central neck lymph node metastases. If a patient had multiple, discrete lymph node metastases, each lymph node was recorded as an individual metastasis. The anatomic location of persistent nodal metastases found on postoperative SPECT/CT was compared with the cervical lymph node levels that were noted to contain metastatic lymph nodes on preoperative imaging and to the lymph node compartments dissected during the initial surgical procedure in order to determine the reason for residual nodal metastases. The reasons for residual lymph node metastases was classified as either incomplete operation, which was defined as residual nodal metastasis in a nodal compartment (central or lateral) that was dissected at the time of initial surgery, or unrecognized nodal involvement, which was defined as the presence of residual lymph node metastasis in an undissected nodal compartment and therefore was presumed to be due to lack of identification of nodal involvement preoperatively on physical exam or any imaging study performed. For example, in patients having total thyroidectomy alone, any residual lymph node metastasis detected on ^{131}I SPECT/CT would be defined as having unrecognized nodal involvement since no neck dissection was performed. In a patient having a total thyroidectomy with a therapeutic central neck dissection for suspicious nodes noted in the central neck on preoperative ultrasound, residual

lymph node metastasis detected on ^{131}I SPECT/CT in the central and lateral neck would be classified as having both incomplete operation for the residual metastatic nodes in the central neck and unrecognized nodal involvement for the metastatic nodes in the lateral neck.

Categorical variables are presented as percentages and are compared for statistical significance via Pearson's chi-square and Fisher's exact tests. Bonferroni's multiple comparisons correction was applied as necessary. Continuous variables are reported as means \pm standard deviation and are compared via independent samples *t*-tests.

Results

There were 352 patients with intermediate or high-risk DTC referred for postoperative radioiodine therapy after initial surgical treatment over the study period. Diagnostic and post-treatment ^{131}I SPECT/CT scans noted 206 (58.5%) patients without nodal metastases and 146 (41.8%) patients with residual nodal metastases consistent with persistent DTC. The demographics of these two groups are noted in Table 1. There was a significant difference between the mean age of patients with nodal metastasis (40.6 years) and without nodal metastasis (49.6 years) ($p < 0.05$). Of the 160 patients less than 45 years old, there were significantly more patients with residual nodal metastasis (86, 53.8%) than without residual nodal metastasis (74, 46.3%) ($p < 0.05$). In contrast, of the 192 patients 45 years old or greater, there were significantly fewer patients with residual nodal metastasis (60, 31.3%) than without residual nodal metastasis (132, 68.8%) ($p < 0.05$). No significant differences in sex, hospital where initial surgery was performed, tumor types, and tumor size were observed between the two study groups. There was no significant difference in the use of preoperative cervical ultrasound between patients with residual nodal metastasis (119, 84.4%) and those without residual nodal metastasis (174, 84.5%). Of the 107 patients who underwent a preoperative CT scan, 57 (40.4%) had residual nodal metastasis and 50 (25.1%) did not have residual nodal metastasis ($p < 0.005$). Of the patients who had both a preoperative ultrasound and a preoperative CT scan performed, five had lateral neck lymph nodes and one had central neck lymph nodes diagnosed on CT scan that were not detected on ultrasound. Conversely, of this same group of patients, four had lateral neck lymph nodes and four had central neck lymph nodes diagnosed on ultrasound that were not detected on CT scan. The 98 patients in the multifocal primary tumor group were the only patients that demonstrated significantly more residual nodal metastases compared with those without multifocal primary tumors: 51 patients with residual nodal metastases (34.9%) had a multifocal primary tumor, while only 47 patients without nodal metastases (22.8%) had a multifocal primary tumor ($p < 0.05$). Patients with T1a tumors had significantly fewer residual nodal metastases [15 (10.3%) with metastases vs. 38 (18.4%) without metastases, $p < 0.05$], while patients with T1b tumors had significantly more residual metastases [41 (28.1%) with metastases vs. 27 (13.1%) without metastases, $p < 0.001$]. There were no significant differences in rates of residual nodal metastases among patients with T2, T3, T4, or Tx disease. Patients with N1a disease had significantly fewer residual nodal metastases [46 (31.5%) with metastases vs. 87 (42.2%) without metastases,

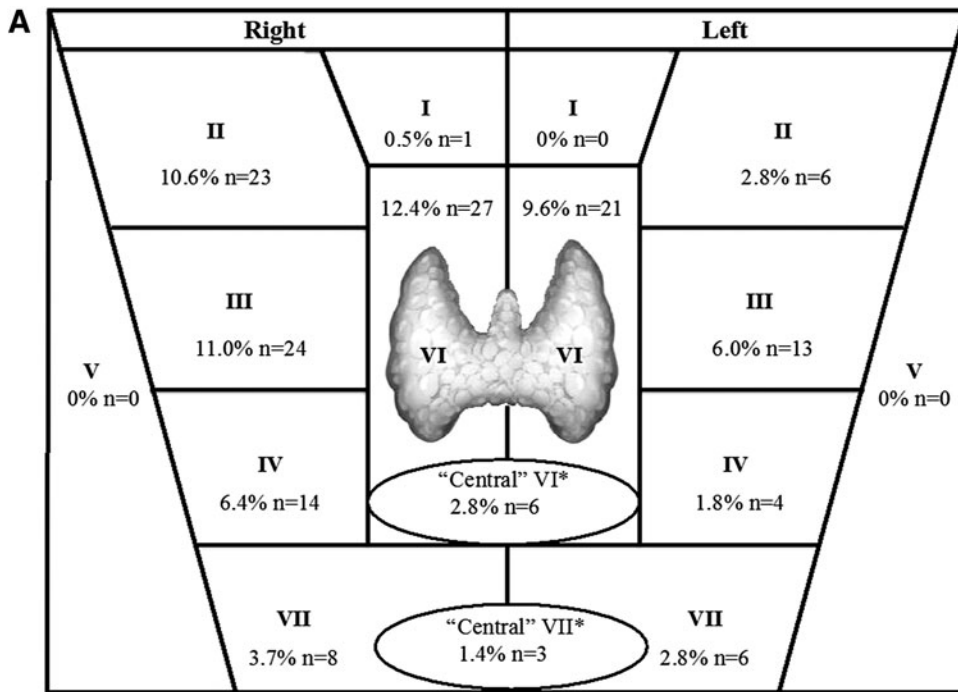
TABLE 1. PATIENT DEMOGRAPHICS AND TUMOR CHARACTERISTICS

	<i>Patients with residual nodal metastasis, n (%)</i>	<i>Patients without residual nodal metastasis, n (%)</i>	<i>p-Value</i>
Number of patients	146	206	
Mean age (years) \pm SD	40.6 \pm 16.8	49.6 \pm 15.7	<0.001
<45	86 (58.9%)	74 (35.9%)	<0.05
\geq 45	60 (41.1%)	132 (64.1%)	<0.05
Sex			
Female	96 (65.7%)	136 (66.0%)	NS
Male	50 (34.3%)	70 (34.0%)	NS
Hospital where initial surgery was performed			
University of Michigan	119 (81.5%)	174 (84.5%)	NS
Other hospital	27 (18.5%)	32 (15.5%)	NS
Preoperative imaging	<i>n</i> = 141	<i>n</i> = 199	
Ultrasound	119 (84.4%)	179 (89.9%)	NS
CT scan	57 (40.4%)	50 (25.1%)	<0.005
Tumor types			
Papillary	142 (97.3%)	195 (94.7%)	NS
Follicular	3 (2.0%)	9 (4.4%)	NS
Hürthle Cell	1 (0.7%)	2 (1.0%)	NS
Lobe involvement			
Left	35 (24.0%)	68 (33.0%)	NS
Right	56 (38.4%)	81 (39.3%)	NS
Multifocal	51 (34.9%)	47 (22.8%)	<0.05
Isthmus	4 (2.7%)	7 (3.4%)	NS
Pyramidal	0 (0%)	1 (0.5%)	NA
Unspecified	0 (0%)	2 (1.0%)	NA
Mean tumor size (cm) \pm SD	2.4 \pm 1.7	2.5 \pm 1.8	NS
Tumor stage			
T1a	15 (10.3%)	38 (18.4%)	<0.05
T1b	41 (28.1%)	27 (13.1%)	<0.001
T2	24 (16.4%)	29 (14.1%)	NS
T3	52 (35.6%)	81 (39.3%)	NS
T4a	13 (8.9%)	26 (12.6%)	NS
T4b	0 (0%)	2 (1.0%)	NS
Tx	1 (0.7%)	3 (1.5%)	NS
Nodal involvement			
N0	22 (15.1%)	30 (14.6%)	NS
N1a	46 (31.5%)	87 (42.2%)	<0.05
N1b	48 (32.9%)	57 (27.7%)	NS
Nx	30 (20.5%)	32 (15.5%)	NS
Distant metastases			
M0	134 (91.8%)	193 (93.7%)	NS
M1	12 (8.2%)	13 (6.3%)	NS
Cancer stage			
Stage I	102 (69.9%)	86 (41.8%)	<0.05
Stage II	5 (3.4%)	10 (4.9%)	NS
Stage III	19 (13.0%)	63 (30.6%)	<0.05
Stage IVA	19 (13.0%)	44 (21.4%)	<0.05
Stage IVB	0 (0%)	2 (1.0%)	NA
Stage IVC	1 (0.7%)	1 (0.5%)	NS

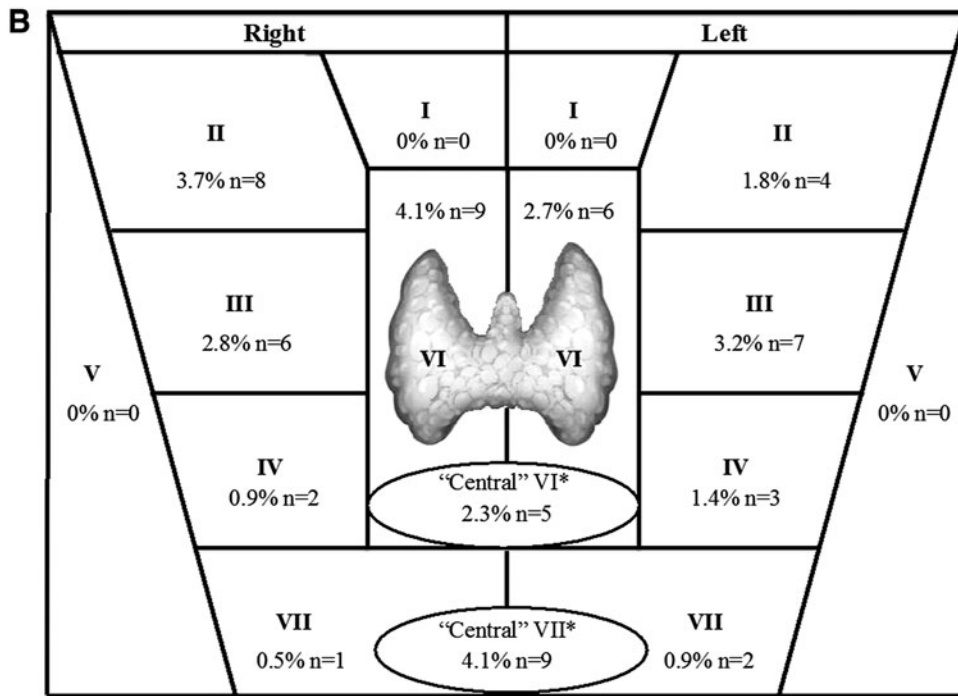
$p < 0.05$]. There were no significant differences in rates of residual nodal metastases among patients with N0, N1b, Nx, M0, or M1 disease. Cancer stage I, stage III, and stage IVA patients showed significant differences ($p < 0.05$) in the incidences of residual nodal metastases. Patients with stage I cancer had significantly more residual nodal metastases [102 (69.9%) with metastases vs. 86 (41.8%) without metastases, $p < 0.05$]. Patients with stage III cancer had significantly fewer residual nodal metastases [19 (13.0%) with metastases vs. 63 (30.6%)

without metastases, $p < 0.05$] and patients with stage IVA cancer also had significantly fewer residual nodal metastases [19 (13.0%) with metastases vs. 44 (21.4%) without metastases, $p < 0.05$].

Residual nodal metastases were categorized as either ipsilateral, 156 (71.6%), or contralateral, 48 (22.0%), relative to the location of primary thyroid tumor (Fig. 1a and 1b). Nodal metastases from multifocal and isthmus primary tumors were categorized into the ipsilateral group. There were



*Denotes nodal metastases that were labeled as "central" without a laterality designation.



*Denotes nodal metastases that were labeled as "central" without a laterality designation.

FIG.1. Distribution of cervical lymph node levels associated with nodal metastases (A) ipsilateral to the primary thyroid tumor (this includes multifocal and isthmus primary tumors) and (B) contralateral to the primary thyroid tumor.

156 (71.6%) nodal metastases ipsilateral to the primary tumor and 48 (22.0%) which were contralateral. No laterality was assigned to 14 (6.4%) central neck (levels VI and VII) metastases on the operative or pathology report.

Among the 146 patients with residual nodal metastases, there were a total of 218 discrete nodal metastases: 102 patients had 1 metastasis, 25 patients had 2 metastases, 12 patients had 3 metastases, 6 patients had 4 metastases, and 1

patient had 6 metastases. The locations of the 218 total nodal metastases were classified based on the defined cervical lymph node levels in Table 2. Of note, 74/218 (33.9%) metastases were found in level VI, making it the level with the highest frequency of residual nodal metastases. The next most frequent regions of nodal metastases were found in the lateral neck: levels III [50 (22.9%)] and II [41 (18.8%)], respectively. Cervical level IV [23 (10.6%)] showed lower

TABLE 2. ANATOMIC LOCATION OF RESIDUAL NODAL METASTASES BASED ON DEFINED CERVICAL LYMPH NODE LEVELS

Cervical neck level	No. of nodal metastases
I	1 (0.5%)
II	41 (18.8%)
III	50 (22.9%)
IV	23 (10.6%)
V	0 (0%)
VI	74 (33.9%)
VII	29 (13.3%)
Total	218 (100%)

frequencies of nodal metastasis than levels II and III in the anterior lateral neck. Out of the 218 total residual metastases, 0 (0.0%) were found in level V and only 1 (0.5%) was found in level I.

Evaluation of the reasons for residual nodal metastases showed that 71 patients (48.6%) had an incomplete operation (the residual metastatic nodes were in a previously dissected compartment), 56 patients (38.4%) had preoperatively unrecognized nodal metastases (the residual nodes were in a previously undissected compartment), and 19 (13.0%) had a combination of both incomplete nodal dissection and unrecognized nodal metastases in more than one compartment (Table 3).

Assessment during long-term follow-up after initial surgery (median follow-up time: 1048.5 days, range: 62–2878 days) showed that 28 of the 146 patients (19.2%) with residual nodal disease went on to have persistent disease after a single dose of radioiodine therapy (Table 4). This suggests that the use of radioiodine therapy in the treatment of residual lymph node metastasis was effective in 80.8% of patients in this study's patient cohort. Of the 28 patients with persistent disease after both surgery and the initial dose of radioiodine, 20 patients underwent additional treatment for DTC, which included 18 (64.3%) who underwent a repeat surgery and 2 (7.1%) who received additional RAI therapy. The remaining 8 patients (28.6%) had not yet undergone additional surgery, RAI or other treatment at the time of completion of this study.

TABLE 4. LONG-TERM FOLLOW-UP OF PATIENTS WITH RESIDUAL NODAL METASTASES

	Patients with residual nodal metastasis on initial diagnostic ¹³¹ I scan with SPECT/CT n=146
Persistent disease following radioactive iodine	28 (19.2%)
Intervention	
Repeat surgery	18 (64.3%)
Repeat radioactive iodine	2 (7.1%)
Surveillance	8 (28.6%)

Discussion

The findings from this study demonstrate that patients with high and intermediate-risk DTC referred for radioiodine therapy after initial surgical treatment have high rates of residual nodal metastasis on highly sensitive diagnostic iodine SPECT/CT scanning. SPECT/CT radioiodine scanning provides a superior image contrast resolution compared with planar radioiodine scans alone and is highly sensitive in detecting residual nodal metastasis and provides more detailed information about the location and extent of regional and distant metastases and is likely the contributing factor for the higher than previously published rates of residual lymph node metastasis after initial treatment (5,7–16). The high incidence of residual nodal metastasis on diagnostic iodine scanning also highlights the lower relative sensitivity of preoperative cervical ultrasound in detecting small volume lymph node metastasis, particularly in the central neck, during the initial evaluation for DTC as compared with postsurgical iodine scanning with SPECT/CT. Residual cervical lymph node metastases may require either remedial surgery with its associated increased risk of complications and/or further radioiodine therapy with its associated risks related to additional radiation exposure (7). The 8% (28/352) rate of persistent disease that required additional treatment in this study is lower than the estimated rates in the current literature of

TABLE 3. ASSOCIATION OF SURGICAL TREATMENTS WITH REASONS FOR RESIDUAL NODAL METASTASES

	No. of patients w/ residual nodal metastasis n=146	TT n=20 (13.7%)	TT + CLND n=95 (65.1%)	TT + CLND + ILND n=21 (14.4%)	TT + CLND + BLND n=10 (6.9%)
Unrecognized nodal involvement	56 (38.4%)	20 (100%)	31 (32.6%)	4 (19%)	1 (10%)
Incomplete operation	71 (48.6%)	0 (0%)	47 (49.5%)	15 (71.4%)	9 (90%)
Both	19 (13%)	0 (0%)	17 (17.9%)	2 (9.6%)	0 (0%)
Cervical neck levels involved					
I	1 (0.7%)	0 (0%)	1 (1.1%)	0 (0%)	0 (0%)
II	8 (5.5%)	3 (15%)	5 (5.3%)	0 (0%)	0 (0%)
III	24 (16.4%)	6 (30%)	13 (13.6%)	3 (14.3%)	2 (20%)
IV	10 (6.8%)	2 (10%)	6 (6.3%)	2 (9.5%)	0 (0%)
V	0 (0%)	0 (0%)	0 (0%)	0 (0%)	0 (0%)
VI	44 (30.1%)	4 (20%)	32 (33.7%)	6 (28.6%)	2 (20%)
VII	15 (10.3%)	2 (10%)	8 (8.4%)	3 (14.3%)	2 (20%)
>1 level involved	44 (30.1%)	3 (15%)	30 (31.6%)	7 (33.3%)	4 (40%)

BLND, bilateral lymph node dissection; CLND, central lymph node dissection; ILND, ipsilateral lymph node dissection; TT, total thyroidectomy.

20–50% and may be a result of patient factors and treatment factors that will require additional study (17–20). Only 14% (20/146) of patients with residual nodal metastasis on postoperative radioiodine scan with SPECT/CT went on to require additional treatment (18 repeat surgery; 2 additional radioiodine) after their first dose of therapeutic radioiodine thus highlighting the effectiveness of therapeutic radioiodine therapy for regional control in patients with small, low volume residual nodal metastasis after initial surgical treatment.

There were 146 (41.8%) patients in this study with residual nodal metastases (persistent DTC) on postoperative diagnostic radioiodine scanning after initially curative intent surgery. Multifocal primary tumors were found to result in residual nodal metastases more frequently than unilateral primary tumors. The most common location for residual nodal metastases for all patients was in central neck (cervical level VI), and to a lesser extent in the lateral neck (levels II and III). The pattern of lymph node metastasis disease progression starting in the central neck and then to progressing to the lateral neck is evident in the results of this study and supports the guideline recommendation to include dissection of at least the ipsilateral central neck when performing a lateral neck dissection for lymph node metastases in patients with regionally advanced DTC (1).

The findings from this study also indicate that both initial preoperative identification and surgical dissection of clinically involved lymph nodes have an influence on the rates of persistent DTC. Improvement in these areas has the potential to lower the incidence of residual nodal metastases, which would lead to decreased recurrence rates and the subsequent need for additional surgical or radioiodine treatments. In this study, residual lymph node metastases occurred due to an incomplete nodal operation slightly more frequently than it was due to preoperative unrecognized nodal involvement, however improvements in both of these two categories may result in a significant decrease in residual nodal metastases. As 38.4% of patients in this study had unsuspected residual metastases, a complete evaluation of the central and lateral neck preoperatively is important to possibly reduce rates of residual metastases. Physical examination is not sensitive enough to detect abnormal lymph nodes, so either cervical ultrasound or cross-sectional imaging is required in patients with DTC to detect clinically abnormal lymph nodes as recommended by ATA guidelines (1). In this study, patients with or without residual nodal metastasis had similar rates of preoperative cervical ultrasound performed, but CT was used more frequently in patients with residual nodal metastasis. This is likely due to a selection bias because in patients with recognized nodal metastasis on ultrasound, CT scan is commonly obtained for further lymph node mapping prior to therapeutic neck dissection. Additionally, this study was not designed to compare the sensitivity of ultrasound and CT in the detection of lymph node metastasis, therefore no conclusions can be made from the data in this study as to whether ultrasound or CT is more effective in the detection of nodal metastasis prior to surgical intervention. The highly sensitive functional nuclear imaging with diagnostic and post-treatment SPECT/CT scans is able to detect early metastases in small, nonenlarged lymph nodes that may appear normal on preoperative cervical ultrasound and/or CT imaging. The use of postoperative diagnostic scintigraphy with SPECT/CT and therapeutic ^{131}I administration in patients with intermediate and high-risk of recurrence allows for treatment of these foci of

residual disease with an appropriate dose of RAI at an early state with curative intent. The increased sensitivity of ^{131}I with SPECT/CT to detect *microscopic* nodal involvement, which may not be recognized on preoperative ultrasound or cross-sectional imaging due to limitations of resolution, will likely contribute to a least a constant low level of persistent DTC after surgical treatment. The presence of clinically suspicious lymph nodes preoperatively should necessitate a nodal dissection of that compartment. However, if *macroscopic* nodal disease is not suspected due to incomplete imaging or lack of recognition of suspicious lymph nodes on imaging, the nodal dissection may be omitted and will lead to residual macroscopic nodal metastasis and the likely need for reoperative lymph node dissection. The ATA guidelines for the treatment of regionally advanced DTC include a recommendation to complete a compartment-oriented dissection of the affected compartments, and “berry picking” or selective neck dissection should be avoided in the initial surgical treatment of these patients (1).

The limitations of this study include that it is a retrospective analysis of a single-center database, which makes the results more difficult to generalize to all thyroid cancer treatment centers. Furthermore, only intermediate and high-risk DTC patients who were referred for RAI treatment were included in this study, which introduces an inherent selection bias. The conclusions of this study can only be applied to this cohort of patients with intermediate and high-risk DTC and not to patients with low risk DTC who were excluded from this study, but who make up the majority of patients with thyroid cancer. An additional limitation is the use of ^{131}I SPECT/CT as the primary outcome measure for residual lymph node metastasis which may not be typical in other institutions. SPECT/CT is likely more sensitive than ultrasound or CT imaging and therefore may detect higher rates of lymph node *micrometastases*, some of which may not have comparable clinical relevance to lymph node *macrometastasis* noted on lower sensitivity imaging studies such as ultrasound or CT. Additionally, FNA was not utilized to confirm the presence of PTC in every suspicious lymph node detected on SPECT/CT, so there is possibility that false positives on ^{131}I SPECT/CT may skew the rates of residual lymph node metastasis toward higher than actual rates.

In conclusion, residual iodine-avid lymph node metastasis is commonly detected on highly sensitive ^{131}I SPECT/CT after initial curative-intent surgery in patients with high-risk differentiated thyroid cancer. The most common anatomic locations for residual nodal metastasis is level VI in the central neck and in levels II and IV in the lateral neck ipsilateral to the primary tumor and special attention should be paid to these areas during surveillance. By anatomic correlation, roughly half of residual lymph node metastases are due to inability to recognize the extent of nodal involvement preoperatively while the other half are due to incomplete compartmental lymph node dissection. Recognition of the common locations of residual lymph node metastases and the causation of this persistent disease may help improve the initial surgical management of patients with differentiated thyroid cancer and reduce the rates of residual disease and subsequent recurrence.

Author Disclosure Statement

No competing financial interests exist.

References

1. Solorzano CC, Carneiro DM, Ramirez M, Lee TM, Irvin GL 2004 Surgeon-performed ultrasound in the management of thyroid malignancy. *Am Surg* **70**:576–580.
2. Shimamoto K, Satake H, Sawaki A, Ishigaki T, Funahashi H, Imai T 1998 Preoperative staging of thyroid papillary carcinoma with ultrasonography. *Eur J Radiol* **29**:4–10.
3. Leboulleux S, Girard E, Rose M, Travagli JP, Sabbah N, Cailhou B, Hartl DM, Lassau N, Baudin E, Schlumberger M 2007 Ultrasound criteria of malignancy for cervical lymph nodes in patients followed up for differentiated thyroid cancer. *J Clin Endocrinol Metab* **92**:3590–3594.
4. Hughes CJ, Shaha AR, Shah JP, Loree TR 1996 Impact of lymph node metastasis in differentiated carcinoma of the thyroid: a matched-pair analysis. *Head Neck* **18**:127–132.
5. Shah JP, Loree TR, Dharker D, Strong EW, Begg C, Vlaminis V 1992 Prognostic factors in differentiated carcinoma of the thyroid gland. *Am J Surg* **164**:658–661.
6. Coburn MC, Wanebo HJ 1992 Prognostic factors and management considerations in patients with cervical metastases of thyroid cancer. *Am J Surg* **164**:671–676.
7. McHenry, CR, Rosen, IB, Walfish P 1991 Prospective management of nodal metastases in differentiated thyroid cancer. *Am J Surg* **162**:353–356.
8. Wang TS, Dubner S, Szynter LA, Heller KS 2004 Incidence of metastatic well-differentiated thyroid cancer in cervical lymph nodes. *Arch Otolaryngol Neck Surg* **130**:110.
9. Hay, ID, Bergstralh, EJ, Goellner, JR, Ebersold, JR, Grant C 1993 Predicting outcome in papillary thyroid carcinoma: development of a reliable prognostic scoring system in a cohort of 1779 patients surgically treated at one institution during 1940 through 1989. *Surgery* **114**:1050–1057.
10. Schlumberger M, Brose M, Elisei R, Leboulleux S, Luster M, Pitoia F, Pacini F 2014 Definition and management of radioactive iodine-refractory differentiated thyroid cancer. *Lancet Diabetes Endocrinol* **2**:356–358.
11. Lin, JD, Chao TC, Huang MJ, Weng HF, Tzen KY 1998 Use of radioactive iodine for thyroid remnant ablation in well-differentiated thyroid carcinoma to replace thyroid reoperation. *Am J Clin Oncol* **21**:77–81.
12. Robbins KT, Clayman G, Levine PA, Medina J, Sessions R, Shaha A, Som P, Wolf GT 2002 Neck dissection classification update: revisions proposed by the American Head and Neck Society and the American Academy of Otolaryngology-Head and Neck Surgery. *Arch Otolaryngol Head Neck Surg* **128**:751–758.
13. Avram AM, Esfandiari NH, Wong KK 2015 Preablation ¹³¹I scans with SPECT/CT contribute to thyroid cancer risk stratification and ¹³¹I therapy planning. *J Clin Endocrinol Metab* **100**:1895–1902.
14. Spanu A, Solinas ME, Chessa F, Sanna D, Nuvoli S, Madeddu G 2009 ¹³¹I SPECT/CT in the follow-up of differentiated thyroid carcinoma: incremental value versus planar imaging. *J Nucl Med* **50**:184–190.
15. Yamamoto Y, Nishiyama Y, Monden T, Matsumura Y, Satoh K, Ohkawa M 2003 Clinical usefulness of fusion of ¹³¹I SPECT and CT images in patients with differentiated thyroid carcinoma. *J Nucl Med* **44**:1905–1910.
16. Chen L, Luo Q, Shen Y, Yu Y, Yuan Z, Lu H, Zhu R 2008 Incremental value of ¹³¹I SPECT/CT in the management of patients with differentiated thyroid carcinoma. *J Nucl Med* **49**:1952–1957.
17. Hassan FU, Mohan HK 2015 Clinical utility of SPECT/CT imaging post-radioiodine therapy: does it enhance patient management in thyroid cancer? *Eur Thyroid J* **4**:239–245.
18. Barwick T, Murray I, Megadmi H, Drake WM, Plowman PN, Akker SA, Chew SL, Grossman AM, Abril N 2010 Single photon emission computed tomography (SPECT)/computed tomography using Iodine-123 in patients with differentiated thyroid cancer: additional value over whole body planar imaging and SPECT. *Eur J Endocrinol* **162**:1131–1139.
19. Toubert M-E, Vija L, Vercellino L, Banayan S, Faugeron I, Berenger N, Meas T, Marzola MC, Chondrogiannis S, Hindie E, Rubello 2014. Additional diagnostic value of hybrid SPECT-CT systems imaging in patients with differentiated thyroid cancer. *Am J Clin Oncol Cancer Clin Trials* **37**:305–313.
20. Gulec SA, Kuker RA, Goryawala M, Fernandez C, Perez R, Khan-Ghany A, Apaza A, Harja E, Harrell M 2016. ¹²⁴I PET/CT in patients with differentiated thyroid cancer: clinical and quantitative image analysis. *Thyroid* **26**:441–448.

Address correspondence to:

David T. Hughes, MD
Department of Surgery
University of Michigan Health System
2920 Taubman Center
1500 East Medical Center Drive
Ann Arbor, MI 48109

E-mail: davhughe@umich.edu